

## Review article

# Valproate-induced hyperammonemic encephalopathy

Segura-Bruna N, Rodriguez-Campello A, Puente V, Roquer J.  
Valproate-induced hyperammonemic encephalopathy.  
Acta Neurol Scand 2006; 114: 1–7. © Blackwell Munksgaard 2006.

Valproate-induced hyperammonemic encephalopathy (VHE) is an unusual complication characterized by a decreasing level of consciousness, focal neurological deficits, cognitive slowing, vomiting, drowsiness, and lethargy. We have thoroughly reviewed the predisposing factors and their screening, the biochemical and physiopathological mechanisms involved, the different treatments described, and those that are being investigated. Etiopathogenesis is not completely understood, although hyperammonemia has been postulated as the main cause of the clinical syndrome. The increase in serum ammonium level is due to several mechanisms, the most important one appearing to be the inhibition of carbamoylphosphate synthetase-I, the enzyme that begins the urea cycle. Polytherapy with several drugs, such as phenobarbital and topiramate, seems to contribute to hyperammonemia. Hyperammonemia leads to an increase in the glutamine level in the brain, which produces astrocyte swelling and cerebral edema. There are several studies that suggest that treatment with supplements of carnitine can lead to an early favorable clinical response due to the probable carnitine deficiency induced by a valproate (VPA) treatment. Development of the progressive confusional syndrome, associated with an increase in seizure frequency after VPA treatment onset, obliges us to rule out VHE by screening for blood ammonium levels and the existence of urea cycle enzyme deficiency, such as ornithine carbamoyltransferase deficiency. Electroencephalography (EEG) is characterized by signs of severe encephalopathy with continuous generalized slowing, a predominance of theta and delta activity, occasional bursts of frontal intermittent rhythmic delta activity, and triphasic waves. These EEG findings, as well as clinical manifestations and hyperammonemia, tend to normalize after VPA withdrawal.

**N. Segura-Bruna, A. Rodriguez-Campello, V. Puente, J. Roquer**

Servei de Neurologia, Hospital del Mar, Barcelona, Spain

Key words: adverse effects; antiepileptic drugs; epilepsy; molecular biology; inherited metabolic disorders; EEG

Nuria Segura-Bruna, Servei de Neurologia, Hospital del Mar, Barcelona, Passeig Marítim, 25-29, 08003 Barcelona, Spain

Tel.: 932483235

Fax: 932483376

e-mail: 94407@imas.imim.es

Accepted for publication March 14, 2006

Valproate (VPA) is a drug commonly used in neurology and psychiatry. Valproate-induced hyperammonemic encephalopathy (VHE) is an unusual, but serious, adverse effect of VPA treatment (1). VHE is a serious disease that can lead to death. It can, however, be reversed if a precocious diagnosis is made (2). It is therefore extremely important to recognize it and discontinue VPA treatment.

### Predisposing causes

The main physiopathological mechanism that leads to VHE is an increased serum ammonia level. There are many causes of hyperammonemia such as urea cycle enzyme deficiency, Reye's syndrome, several drugs (VPA, 5-Fluorouracil, and salicylates), and renal or hepatic failure (Table 1) (3).

**Table 1** Hyperammonemia causes

Enzyme defects in urea cycle	OTC deficiency CPS-I deficiency NAGS deficiency AS deficiency AL deficiency Arginase deficiency
Fatty acid oxidation defects	Acyl-CoA dehydrogenase deficiency Systemic carnitine deficiency
Congenital lactic acidosis	Pyruvate dehydrogenase deficiency Pyruvate carboxylase deficiency Mitochondrial diseases
Organic acidemias	Isovaleric acidemia Propionic acidemia Methylmalonic acidemia Glutaric acidemia type II Multiple carboxylase deficiency Beta-ketothiolase deficiency
Dibasic amino acid transport defect	Lysinuric protein intolerance Hyperammonemia-hyperornithinemia-homocitrullinuria
Drugs	Valproate 5-Fluorouracil Salicylates
Liver diseases	Acute or chronic liver diseases (cystic fibrosis, Wilson disease, biliary atresia, AAT deficiency...)
Renal diseases	Urinary tract infections with <i>Proteus mirabilis</i> , <i>Staphylococcus</i> or <i>Corynebacterium</i>
Reye's syndrome, parenteral hyperalimentation	
Transient hyperammonemia of the newborn	

AAT,  $\alpha$ -1-antitrypsin deficiency; AL, argininosuccinic acid lyase; AS, argininosuccinic synthetase; CPS-I, carbamoylphosphate synthetase-I; NAGS, *N*-acetylglutamate synthetase; OTC, ornithine transcarbamylase.

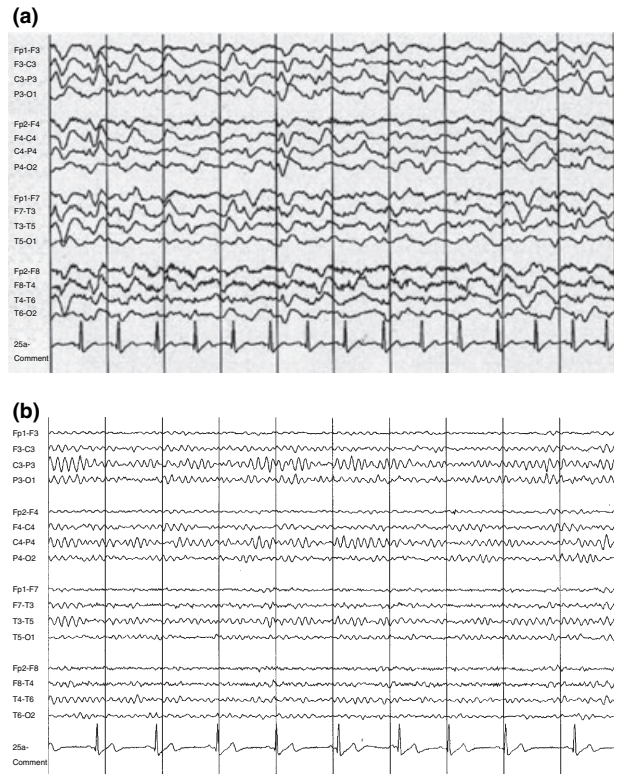
Ornithine transcarbamylase (OTC) or ornithine carbamoyltransferase deficiency is the most commonly inherited cause of hyperammonemia. About 1 of 30,000 women in the United States is heterozygous for this urea cycle defect (4). OTC deficiency is an important risk factor for developing VHE in patients taking VPA. Therefore, recommendations for the screening of this and other urea cycle enzyme deficiencies include:

1. Those patients with a known family history of OTC deficiency.
2. Those patients who, after beginning treatment with VPA, develop unexplained episodes of confusion, especially in the setting of known stress factors (i.e., sepsis); aversion to protein (headache causing); and a family history of unexplained death in male children (especially males, because OTC is an X-linked disorder). Renal and liver functions, blood ammonia level, and excretion of urinary orotic acid should be screened. A provocative test such as allopurinol

loading may also be carried out. This test consists of taking a single oral dose of allopurinol, which significantly increases the urinary excretion of orotic acid in OTC-deficient patients.

Therefore, in OTC deficiency we find high blood levels of ammonium, glutamine, and alanine, low blood levels of citrulline, and near-undetectable blood levels of arginine in combination with an increased excretion of urinary orotic acid (Fig. 1).

When hyperammonemia occurs in the neonatal period, some laboratory studies such as plasma and urinary amino acids, serum glucose, arterial blood gases, bicarbonate, lactate, citrulline, carnitine, urinary ketones, and urinary orotate can help make a specific diagnosis. Thus, organic acidemias should be suspected when hyperammonemia is associated with acidosis, ketosis, and low bicarbonate level. Some kinds of organic acidemias are also associated with hyperglycinemia and hypoglycemia. On the other hand, hyperammonemia, in addition to acidosis, ketosis, and increased lactate



**Figure 1.** (a) EEG shows an irregular, continuous, severe and diffuse slowing with predominance of rhythmical theta and delta activity, which are diffuse signs of severe encephalopathy. (b) EEG made 9 days after VPA withdrawal and the first EEG shows an improvement with mild slowing and predominance of rhythmical theta activity, maximum at 8 Hz, which are diffuse signs of mild encephalopathy.

and citrulline, indicates pyruvate carboxylase deficiency. In contrast, urea cycle defects or transient hyperammonemia of the newborn causes hyperammonemia with respiratory alkalosis. In argininosuccinic acid synthetase deficiency plasma the citrulline level is very high ( $> 1000 \mu\text{mol/l}$ ), whilst in argininosuccinic lyase deficiency the citrulline level is only mildly increased ( $100\text{--}300 \mu\text{mol/l}$ ). Plasma citrulline levels are almost undetectable in carbamoylphosphate synthetase-I (CPS-I) and OTC deficiencies. In a similar way to OTC deficiency, *N*-acetylglutamate synthetase (NAGS) deficiency requires a liver biopsy for a definite diagnosis.

### **Clinical findings**

Valproate-induced hyperammonemic encephalopathy is a serious disease that can lead to death. It can, however, be reversed if a precocious diagnosis is made (2) and VPA treatment is discontinued.

Valproate-induced hyperammonemic encephalopathy is clinically characterized by an acute or subacute decreasing level of consciousness that goes from drowsiness to lethargy and coma, ataxia, vomiting, and focal neurological deficit. Low-grade fever (5), amblyopia, and an increase in the frequency of seizures (6) can also be found. This finding can even lead to an increase in VPA dose before diagnosis, with the consequent worsening.

### **Laboratory findings**

Laboratory tests usually show a normal liver function with hyperammonemia. A relationship between the daily doses of VPA and the appearance and severity of VHE has not been found (7). Therefore, there does not seem to be any relationship between the development of VHE and serum VPA levels. Blood VPA levels are within therapeutic ranges in most VHE cases (8). No correlation between clinical severity and higher blood ammonium levels when hyperammonemia is confirmed has been found (7). Other laboratory tests related to OTC deficiency have been described previously.

### **Electroencephalography (EEG)**

An EEG study usually shows diffuse signs of severe encephalopathy. The main findings are irregular, continuous, severe, and diffuse slowing with a predominance of rhythmical theta and delta activity. Occasionally, triphasic waves can be found, with bursts of frontal intermittent rhythmic delta activity (Fig. 1A).

## **Valproate-induced hyperammonemic encephalopathy**

Once VPA is discontinued, all these findings can be reversed, particularly if there is an early diagnosis. Progressive clinical improvement correlates with the normalization of EEG and serum ammonium levels (Fig. 1B).

### **Magnetic resonance imaging (MRI)**

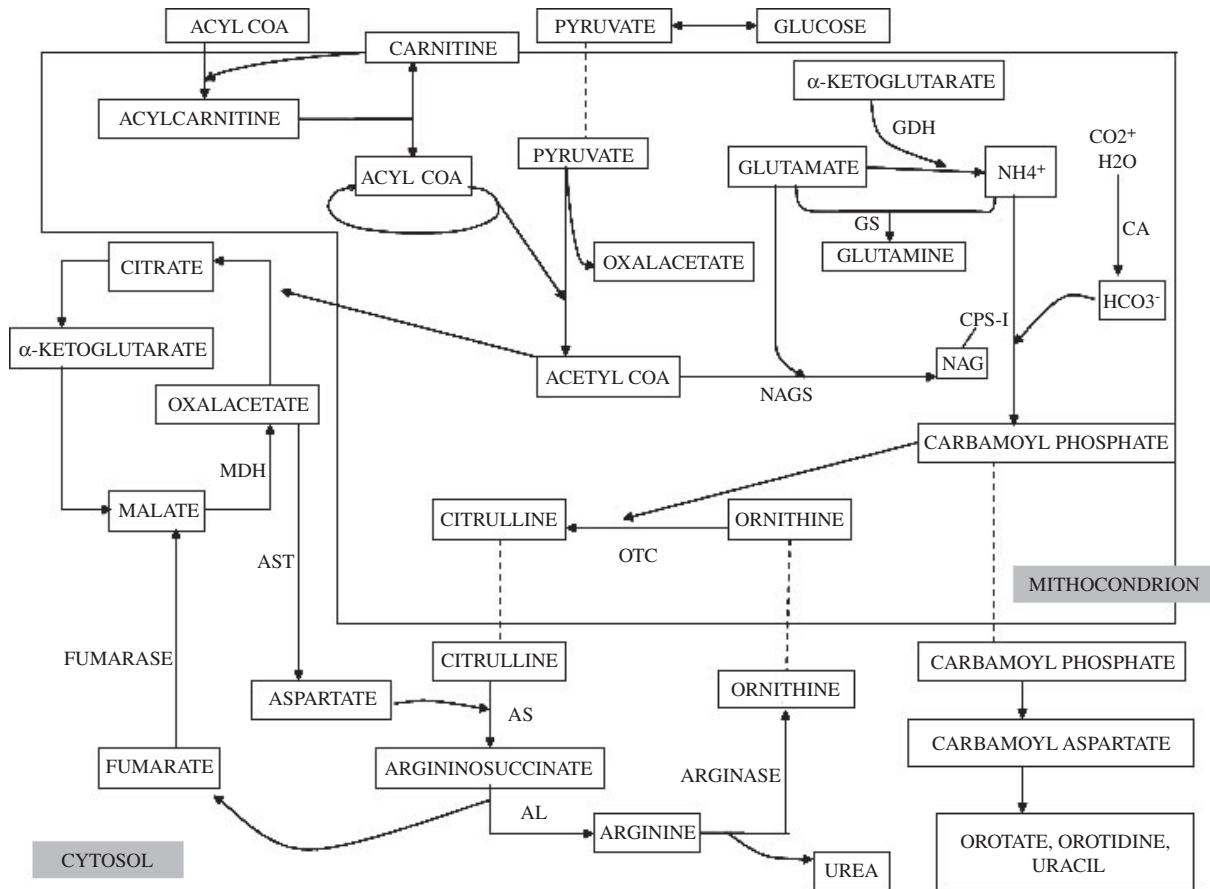
A previous study showed bilateral T2-hyperintense lesions in MRI located in the cerebellar white matter and globus pallidus. Proton MR spectroscopy (MRS) showed a severe depletion of *myo*-inositol and choline with glutamine excess, and a moderate decrease of *N*-acetyl aspartate (9, 10).

### **Pathologic findings**

Most of the information about pathologic anatomy changes in VHE has been collected from the extensive number of articles published by Sobaniec-Lotowska (11–13). These are studies concerning cerebellar and temporal lobe ultrastructure changes in rats in VPA encephalopathy induced by chronic administration of VPA (9 and 12 months), and after its withdrawal for 1 and 3 months. In these studies, damage to astrocytes of the hippocampal gyre cortex and neocortex of the temporal lobe, mainly in the pyramidal layer, has been observed. The observed ultrastructural changes are cell swelling, decrease in the number of gliofilaments, and empty cytoplasmic vacuoles. Damage to Purkinje cells has been shown, mainly in mitochondria, but also in Golgi complex, granular and smooth endoplasmic reticulum, leading to the inhibition of oxidative phosphorylation, abnormal protein synthesis, and cell death. Most of these abnormalities tend to disappear 3 months after VPA withdrawal. However, damage to the synaptic junctions in the cerebellar cortex, mainly in the molecular layer, did not appear to be repaired 3 months after VPA withdrawal, and the abnormalities observed may suggest damage caused by ischemia because of changes in microcirculation (11–13).

### **Etiopathogenesis and therapeutic possibilities**

The pathogenesis of VHE is not completely understood. Hyperammonemia has been postulated as the main cause of encephalopathy, although a high blood ammonium level has not been observed in all cases of VHE. Treatment with VPA can lead to hyperammonemia because of several mechanisms, the hepatic and renal effect of VPA and their metabolites being very important. On the one hand, increased uptake of glutamine,



**Figure 2.** Urea cycle and Krebs cycle. AL, argininosuccinic acid lyase; AS, argininosuccinic acid synthetase; AST, aspartate amino transferase; CA, carbonic anhydrase; CPS-I, carbamoylphosphate synthetase-I; GDH, glutamate dehydrogenase; GS, glutaminase; MDH, malate dehydrogenase; NAGS, *N*-acetylglutamate synthetase; OTC, ornithine transcarbamylase.

and the release of ammonium in the kidneys, favor hyperammonemia through stimulation of kidney glutaminase in the renal cortex, and this seems to be produced by a VPA metabolite, sodium 2-propyl-4-pentenoate (4-en-VPA). Nevertheless, it appears that this mechanism is responsible for less than 25% of the increase in blood ammonium levels (14).

On the other hand, a VPA metabolite (propionate) is remarkable for producing a decrease of hepatic *N*-acetylglutamate (NAG) levels. This leads to the inhibition of hepatic mitochondrial CPS-I, the enzyme that begins the urea cycle (a chemical reaction set whose aim is to produce urea by removing two ammonium ions in each cycle) (8, 15, 16) (Fig. 2). Another VPA metabolite, 4-en-VPA, causes a decrease in the availability of acetyl-coenzymeA (acetyl-CoA) due to the formation of valproyl-CoA and its metabolites. Acetyl-CoA, together with glutamate, is needed to produce NAG. As a result, this leads to a decrease in hepatic NAG which causes an increase in blood ammonium levels as explained previously (8, 14, 15, 17, 18).

Thus, urea cycle enzyme deficiencies, such as OTC deficiency and carnitine deficiency (congenital or acquired, e.g., from hepatic failure, strict vegetarian diet), concomitant to the treatment with VPA, favor hyperammonemia and the development of VHE. OTC deficiency is an X-linked disorder and is the most commonly inherited cause of hyperammonemia (4, 19–21). OTC is one of the urea cycle enzymes. It catalyzes the reaction of carbamoylphosphate and ornithine to produce citrulline. As a result, in OTC deficiency there is an accumulation of carbamoylphosphate in the mitochondrion that leaks out of the cytoplasm to the pyrimidine synthesis pathway which increases urinary orotic acid excretion (19) (Fig. 2). Therefore, patients with VHE should be screened for OTC deficiency. This occurs mainly in women with VHE, because most men with OTC deficiency die in the neonatal period. Heterozygote females, however, may be either asymptomatic or have an aversion to protein until the development of VHE. Screening should be made for urinary orotic acid level (which would be increased, and it would also

raise with the allopurinol test) and blood citrulline level (which would be decreased). The most certain diagnosis, however, is given by DNA analysis or biopsy (OTC deficiency in hepatocytes or enterocytes) (19, 20).

Some investigators have found a decrease in carnitine concentrations in plasma and skeletal muscle, maximum at day 14 of VPA treatment and reversible after VPA withdrawal (14, 22–24). Consequently, VHE patients might benefit (especially those with fulminant hepatic failure) from an oral supplement of L-carnitine (25, 26), with 100 mg/kg/day (26–28) at first, followed by 25 mg/kg/8 h (29). However, the benefit of treatment with L-carnitine in VHE patients without fulminant hepatic failure is under discussion. Also not clear are the dose and pathway to be used (oral or endovenous), because no published studies have demonstrated statistically significant changes in ammonium kinetics in patients treated with L-carnitine and controls (27). There are studies that prefer an endovenous line before oral dose in the treatment with L-carnitine (25). A Pediatric Neurology Advisory Committee in 1996 recommended the L-carnitine endovenous treatment, 150–500 mg/kg/day, in VPA-induced hepatotoxicity and VPA overdose, and also recommended 100 mg/kg/day oral L-carnitine dose in VHE, as mentioned previously (28). Furthermore, carnitine seems to contribute to a more rapid decrease in blood ammonium levels, and this could lead to an early favorable clinical response, even though it is known that the initial blood ammonium level is not correlated with the severity of clinical VHE (27, 29). Related to this, Gidal et al. postulated that a significant reduction in blood ammonium levels occurred in those patients with VPA treatment who, after taking a protein diet, had ingested a supplement with 50 mg/kg/day oral L-carnitine (14). Another study suggested a higher risk of diabetic patients developing VHE due to the effect of VPA and diabetes of decreasing plasma carnitine levels (30). In contrast, Stadler et al. concluded that VPA treatment did not reduce carnitine level in adults because the kidney adapted to conserve carnitine (23).

Ammonium toxicity is mediated by the excessive activation of the NMDA-type of glutamate receptors, mainly in acute hyperammonemia (31). The protective effect of carnitine (and probably other compounds with a trimethylamine group) against ammonium toxicity seems to be produced due to the action of glutamate against neurotoxicity, with an increase in the binding affinity of glutamate for metabotropic glutamate receptors (32).

Furthermore, there are many drugs, such as topiramate and phenobarbital, which favor hyper-

ammonemia, because of the inhibition of the cerebral glutamine synthetase. This enzyme catalyzes the reaction that produces glutamine from the two compounds, ammonium and glutamate (Fig. 2). This glutamate is taken up by astrocytes as a protective effect against excitotoxicity (23, 33). It has also been demonstrated that phenytoin, phenobarbital, and carbamazepine lead to an increase in 4-en-VPA which produces a decrease in acetyl-CoA availability, and this causes a decrease in NAG. As a consequence, an increase in serum ammonium levels is produced, which explains the effect of polytherapy in the development of VHE (28). On the other hand, topiramate is also an inhibitor of carbonic anhydrase, which leads to hyperammonemia because it restricts the way of urea cycle. This synergic effect of VPA and topiramate could explain the relationship in VHE patients that have been taking a concomitant treatment with topiramate (6, 34). Furthermore, it has been suggested that high serum ammonium levels and low carnitine levels are more pronounced in those patients with polytherapy (VPA, phenytoin, and phenobarbital) than in those with monotherapy with VPA (35). VHE has also been related to a concomitant treatment with VPA and pivmecillinam, also known to decrease serum carnitine concentration (36).

Other drugs, such as salicylate, favor hyperammonemia by facilitating the development of VHE (this fact could explain a possible physiopathological relationship with Reye's syndrome in children) (17, 37). This increase in serum ammonium levels has not been observed with other non-steroidal anti-inflammatory drugs, such as ibuprofen and naproxen. And even paracetamol appears to diminish the blood ammonium level (37).

The excessive inhibition of GABA due to the use of several drugs at the same time, which act over the GABA receptor, could lead to clinical encephalopathy (6, 34). Furthermore, ammonium seems to have an amplifying effect, direct and indirect, over the GABAergic neurotransmission, and is probably related to its serum level, producing either depression of the central nervous system or a neuroexcitatory effect with seizures (38).

The increase in seizure frequency in VHE could be explained by the toxicity that high ammonium levels have on astrocytes, leading to an inhibition of glutamate uptake by the cell, and the consequent neuronal damage and cerebral swelling. Ammonium is conjugated in the brain with  $\alpha$ -ketoglutarate (and this reaction is catalyzed by glutamate dehydrogenase enzyme) to form glutamate (Fig. 1). Extracellular glutamate accumulation could produce damage by excitotoxicity with the

consequent increase in frequency of seizures (6, 7). On the other hand, glutamate production through the excess of ammonium could lead to depletion of  $\alpha$ -ketoglutarate in the brain which produces a block in Krebs cycle. Therefore, the absence of oxidative phosphorylation and Krebs cycle activity could lead to irreparable cell damage and neuronal death (33).

The mechanism through which hyperammonemia leads to encephalopathy could be explained by the mechanism explained previously and, also by the increase in serum glutamine levels (due to the excess of ammonium that would conjugate with glutamate to form glutamine). This, together with the inhibition of glutamine release from astrocytes that are exposed to ammonium, leads to an increased glutamine level in the astrocyte. These raised glutamine levels increase intracellular osmolarity, with the consequent entry of water into the astrocytes, which then swell. This impedes the energetic metabolism of the astrocyte, leading to cerebral edema and a higher intracranial pressure (7). Osmotic factors are, therefore, very important in hyperammonemia and, even if glutamine acts as an increased organic osmolyte, *myo*-inositol acts as a compensatory decreased organic osmolyte in hyperammonemic states (39). This is in agreement with the severe depletion of *myo*-inositol shown in proton MRS in a VHE patient (9, 10).

In agreement with this, Takahashi et al. managed to prevent cerebral edema in hyperammonemic rats through the irreversible inhibition of the enzyme glutamine synthetase using the stereoisomer L-methionine S-sulfoximine (MSO). This prevents the increase in glutamine in the astrocyte and its osmotic effect (40, 41). It has been suggested, therefore, that the group of hyperammonemic rats which were treated with MSO had a higher plasma ammonium level, and also a lower glutamine level, in the brain than those untreated, with the consequent decrease in cerebral water percentage. All these findings would suggest that the accumulation of glutamine in the astrocyte is necessary for cerebral swelling, and that hyperammonemia on its own is not enough to develop VHE (39). In hyperammonemic states the cerebral glutamine level, normally 5 mmol/kg of brain, increases to 18 mmol/kg. An increase in extracellular potassium activity in the brain in hyperammonemic states – an effect that has also been attenuated by MSO – has been suggested. However, the probable adverse effect of MSO in reducing the seizure threshold which has been postulated in several studies in rats (although with the highest MSO dose range) and, also, clinical psychomotor agitation and hallucinations which occurred in a study

with terminal cancer patients, have obstructed the chance of using MSO as a VHE treatment. The MSO dose and the type of stereoisomer used has not been described in these studies (39).

## Conclusion

The development of progressive confusional states, sometimes severe, and sometimes coexisting with the increase in frequency of seizures after the onset of VPA treatment (and also after the onset of any other treatment with topiramate, phenobarbital, or pivmecillinam in a patient in concomitant treatment with VPA) obliges us to rule out VHE. In these patients, EEG is characterized by a severe encephalopathy that tends to normalize after VPA withdrawal. Therefore, when a VHE diagnosis is suspected the serum ammonium level and, if possible, the blood glutamate level should be observed. Moreover, urea cycle enzyme deficiencies, mainly OTC deficiency through blood ornithine level and urinary orotic acid level, a metabolic pathway involved in VHE physiopathology (4, 42), should be screened.

## References

1. KAY JD, HILTON-JONES D, HYMAN N. Valproate toxicity and ornithine carbamoyltransferase deficiency. *Lancet* 1986;**2**:1283–4.
2. HAWKES ND, THOMAS GAO, JUREWICZ A et al. Non-hepatic hyperammonaemia: an important, potentially reversible cause of encephalopathy. *Postgrad Med J* 2001;**77**:717–22.
3. ELSAS LJ, LONGO N, ROSENBERG LE. Enfermedades hereditarias del metabolismo de los aminoácidos y por depósito de los mismos. In: Fauci AS, Harrison TR, eds. *Principios de Medicina Interna*. Interamericana de España, S.A.U.: McGraw-Hill, 1998;2497–500.
4. OECHSNER M, STEEN C, STÜRENBURG HJ, KOHLSCÜTTERB A. Hyperammonaemic encephalopathy after initiation of valproate therapy in unrecognised ornithine transcarbamylase deficiency. *J Neurol Neurosurg Psychiatry* 1998;**64**:680–2.
5. O'NEIL M, DUBREY RW, GROCOTT-MASON RM. Valproate encephalopathy and hyperammonaemia. *Postgrad Med J* 2002;**78**:316–7.
6. HAMER HM, KNAKE S, SCHOMBURG U, ROSENOW F. Valproate-induced hyperammonemic encephalopathy in the presence of topiramate. *Neurology* 2000;**54**:230–2.
7. VERROTTI A, TROTTA D, MORGESSE D, CHIARELLI F. Valproate-induced hyperammonemic encephalopathy. *Metab Brain Dis* 2002;**17**:367–73.
8. CHEN W-T, YEN D-J, YU H-Y, LIAO K-K. Valproate-induced encephalopathy. *Chin Med J* 2001;**64**:474–8.
9. ZIYEH S, THIEL T, SPREER J, KLISCH J, SCHUMACHER M. Valproate-induced encephalopathy: assessment with MR imaging and 1H MR spectroscopy. *Epilepsia* 2002;**43**:1101–5.
10. TAKANASHI J, KURIHARA A, TOMITA M et al. Distinctly abnormal brain metabolism in late-onset ornithine transcarbamylase deficiency. *Neurology* 2002;**59**:210–4.

## Valproate-induced hyperammonemic encephalopathy

11. SOBANIEC-LOTOWSKA ME. Ultrastructure of astrocytes in the cortex of the hippocampal gyrus and in the neocortex of the temporal lobe in experimental valproate encephalopathy and after withdrawal. *Int J Exp Pathol* 2003;**84**:115.
12. SOBANIEC-LOTOWSKA ME. Ultrastructure of synaptic junctions in the cerebellar cortex in experiments valproate encephalopathy and after terminating chronic application of the antiepileptic. *Folia Neuropathol* 2002;**40**:87–96.
13. SOBANIEC-LOTOWSKA ME. Ultrastructure of Purkinje cells and their dendritic processes in the rat cerebellar cortex in experimental encephalopathy induced by chronic application of valproate. *Int J Exp Pathol* 2001;**82**:337.
14. GIDAL BE, INGLESE CM, MEYER JF, PITTERLE ME, ANTONOPOULOS J, RUST RS. Diet-and valproate-induced transient hyperammonemia: effect of L-carnitine. *Pediatr Neurol* 1997;**16**:301–5.
15. KATANO H, FUKUSHIMA T, KARASAWA K, SUGIYAMA N, OHKURA A, KAMIYA K. Primidone-induced hyperammonemic encephalopathy in a patient with cerebral astrocytoma. *J Clin Neurosci* 2002;**9**:79–81.
16. COULTER DL, ALLEN RJ. Secondary hyperammonemia: a possible mechanism for valproate encephalopathy. *Lancet* 1980;**2**:1310–1.
17. CODE FX, RABIER D, CATHÉLINERAU L, GRIMBER G, PARVY P, KAMOUN P. A mechanism for valproate-induced hyperammonemia. *Adv Exp Med Biol* 1982;**153**:153–61.
18. HOLOWACH THURSTON J, CARROLL JE, HAUHART RE, SCHIRO JA. A single therapeutic dose of valproate affects liver carbohydrate, fat, adenylate, amino acid, coenzyme A, and carnitine metabolism in infant mice: possible clinical significance. *Life Sci* 1985;**36**:1643–51.
19. VAINSTEIN G, KORZETS Z, POMERANZ A, GADOT N. Deepening coma in a epileptic patient: the missing link to the urea cycle. *Nephrol Dial Transplant* 2002;**17**:1351–3.
20. LEAO MMD. Valproate as a cause of hyperammonemia in heterozygotes with ornithine-transcarbamylase deficiency. *Neurology* 1995;**45**:593–4.
21. HONEYCUTT D, CALLAHAN K, RUTLEDGE L, EVANS B. Heterozygote ornithine transcarbamylase deficiency presenting as symptomatic hyperammonemia during initiation of valproate therapy. *Neurology* 1992;**42**:666–8.
22. TEIN I, XIE ZW. Reversal of valproic acid-associated impairment of carnitine uptake in cultured human skin fibroblasts. *Biochem Biophys Res Commun* 1994;**204**:753–8.
23. STADLER DD, BALE JF, CHENARD CA, REBOUCHE CJ. Effect of long-term valproic acid administration on the efficiency of carnitine reabsorption in humans. *Metabolism* 1999;**48**:74–9.
24. BEVERSDORF D, ALLEN C, NORDGREN R. Valproate-induced encephalopathy treated with carnitine in an adult. *J Neurol Neurosurg Psychiatry* 1996;**61**:211.
25. BOHAN TP, HELTON E, MACDONALD I et al. Effect of L-carnitine treatment for valproate-induced hepatotoxicity. *Neurology* 2001;**56**:1405–9.
26. OSUNA MT, BURCET J, RAMIÓ L, USTRELL X, SILVA Y, MOLINS A. Encefalopatía hiperamoniémica asociada al uso de valproato sódico. *Neurología* 2003;**18**:347–50.
27. SZTAINKRYCER MD. A reply to 'Carnitine' and 'Role of carnitine in valproic acid toxicity'. *J Toxicol Clin Toxicol* 2003;**41**:901–2.
28. MCCALL M, BOURGEOIS JA. Valproic acid-induced hyperammonemia: a case report. *J Clin Psychopharmacol* 2004;**24**:521–6.
29. VOSSLER DG, WILENSKY AJ, CAWTHON DF et al. Serum and CSF glutamine levels in valproate-related hyperammonemic encephalopathy. *Epilepsia* 2002;**43**:154–9.
30. AVERBUCH-HELLER L, BEN-HUR T, RECHES A. Valproate encephalopathy and hypocarnitinaemia in diabetic patients. *J Neurol* 1994;**241**:567–9.
31. FELIPO V, BUTTERWORTH RF. Neurochemistry of ammonia. *Neurochem Int* 2002;**41**:79.
32. LLANSOLA M, ERCEG S, HERNÁNDEZ-VIADEL M, FELIPO V. Prevention of ammonia and glutamate neurotoxicity by carnitine: molecular mechanisms. *Metab Brain Dis* 2002;**17**:389–97.
33. SUÁREZ I, BODEGA G, FERNÁNDEZ B. Glutamine synthetase in brain: effect of ammonia. *Neurochem Int* 2002;**41**:123–42.
34. GAIL E, SOLOMON GE. Valproate-induced hyperammonemic encephalopathy in the presence of topiramate. *Neurology* 2000;**55**:606.
35. SHAKOOR KA, KHAN K. Valproic acid-induced hepatotoxicity and protective role of carnitina. *Pakistan J Pathol* 1997;**8**:133–4.
36. LOKRANTZ CM, ERIKSSON B, ROSEN I, ASZTELY F. Hyperammonemic encephalopathy induced by a combination of valproate and pivmecillinam. *Acta Neurol Scand* 2004;**109**:297–301.
37. UETRECHT JP. Salicylate potentiates valproate-induced hyperammonemia in the rat. *Pharmacology* 1987;**34**:279–85.
38. BASILE AS. Direct and indirect enhancement of GABAergic neurotransmission by ammonia: implications for the pathogenesis of hyperammonemic syndromes. *Neurochem Int* 2002;**41**:115–22.
39. BRUSILOV SW. Hyperammonemic encephalopathy. *Medicine* 2002;**81**:240–9.
40. TAKAHASHI H, KOEHLER RC, BRUSILOV SW, TRAYSTMAN RJ. Inhibition of brain glutamine accumulation prevents cerebral edema in hyperammonemic rats. *Am J Physiol Heart Circ Physiol* 1991;**261**:825–9.
41. WILLARD-MACK CL, KOEHLER RC, HIRATA T et al. Inhibition of glutamine synthetase reduces ammonia-induced astrocyte swelling in rat. *Neuroscience* 1996;**71**:589–99.
42. SHEALI G, SHAJI M, MADHULIKA K, VEENA K. Intermittent hyperammonemic encephalopathy in a child with ornithine transcarbamylase deficiency. *Indian J Pediatr* 2004;**71**:645–8.